

# A stepwise electrocardiographic algorithm for differentiation of mid-septal vs. apical right ventricular lead positioning: the SPICE ECG substudy

George Andrikopoulos<sup>1\*</sup>, Stylianos Tzeis<sup>1</sup>, Stefan Asbach<sup>2</sup>, Verena Semmler<sup>3</sup>, Carsten Lennerz<sup>3</sup>, Ulrich Solzbach<sup>4</sup>, Christian Grebmer<sup>3</sup>, Axel Kloppe<sup>5,6</sup>, Norbert Klein<sup>7</sup>, Socratis Pastromas<sup>1</sup>, Jürgen Biermann<sup>2</sup> and Christof Kolb<sup>3</sup>, on Behalf of the SPICE Study Investigators

<sup>1</sup>Department of Cardiology, Henry Dunant Hospital, 107 Mesogion Avenue, Athens 115 26, Greece; <sup>2</sup>Department of Cardiology and Angiology I, Heart Centre Freiburg University, Freiburg, Germany; <sup>3</sup>Deutsches Herzzentrum München, Klinik für Herz- und Kreislauferkrankungen, Abteilung für Elektrophysiologie, Faculty of Medicine, Technische Universität München, Munich, Germany; <sup>4</sup>Ostalbkrankenhaus, Abteilung für Innere Medizin II, Aalen, Germany; <sup>5</sup>Klinikum Lüdenscheid, Abteilung für Innere Medizin III, Lüdenscheid, Germany; <sup>6</sup>Berufsgenossenschaftliches Universitätsklinikum Bergmannsheil, Medizinische Klinik II, Ruhr Universität Bochum, Bochum, Germany; and <sup>7</sup>Universitätsklinikum Leipzig, Abteilung für Kardiologie und Angiologie, Leipzig, Germany

Received 19 August 2014; accepted after revision 6 November 2014

## Aims

Right ventricular (RV) septum is a non-apical site targeted during lead implantation. Electrocardiographic (ECG) recognition of mid-septal lead location is challenging. The aim of the study is to determine ECG correlates of RV mid-septal pacing.

## Methods and results

The present study is a pre-specified analysis of a prospective, multicenter study, which randomized recipients of an implantable cardioverter defibrillator to an apical vs. mid-septal RV lead positioning. Following implantation, a 12-lead ECG was recorded during intrinsic rhythm and RV pacing. In total, 227 patients, 121 in the apical group (76.9% males,  $67.1 \pm 11.3$  years) and 106 in the mid-septal group (82.1% males, age  $64.7 \pm 12.7$  years) were included. Apically as compared with septally paced patients had significantly longer paced QRS duration ( $177.0 \pm 25.0$  vs.  $170.4 \pm 21.7$ , respectively,  $P = 0.03$ ) and significantly more leftward paced QRS axis ( $-71.6 \pm 33.3^\circ$  vs.  $9.4 \pm 86.5^\circ$ , respectively,  $P < 0.001$ ). A significantly higher proportion of patients in the mid-septal as compared with the apical group displayed predominantly positive QRS in lead V6 (62.3 vs. 4.1%,  $P < 0.001$ ), predominantly positive QRS in any of the inferior leads (53.8 vs. 4.1%,  $P < 0.001$ ), and a QR pattern in lead aVL (53.3 vs. 3.3%,  $P < 0.001$ ). These ECG correlates were incorporated in a stepwise algorithm with total sensitivity of 87% and specificity of 90% for the identification of a mid-septal lead location.

## Conclusion

A mid-septal lead location may be identified using a simple stepwise algorithm, based on the presence of positive QRS in lead V6, positive QRS in any of the inferior leads, and a QR pattern in lead aVL.

## Keywords

Pacing • Electrocardiogram • Septal • Apical • Algorithm

## Introduction

Since the advent of cardiac pacing, the right ventricular (RV) apex has been considered the typical site of endocardial lead positioning. However, accumulating evidence has documented the detrimental

effect of apical pacing on cardiac function and patient outcome.<sup>1,2</sup> From a pathophysiological perspective, apical pacing results in abnormal electrical activation and myocardial contraction pattern, functional mitral regurgitation, adverse left ventricular remodelling, and unfavourable alterations in cardiac metabolism, regional perfusion

\* Corresponding author. Tel: +302106972000; fax: +302106972200, E-mail address: andrikop@hotmail.com

Published on behalf of the European Society of Cardiology. All rights reserved. © The Author 2015. For permissions please email: journals.permissions@oup.com.

### What's new?

- Predominantly positive QRS in lead V6, predominantly positive QRS in any of the inferior leads, and a QR pattern in lead aVL are electrocardiographic (ECG) correlates of mid-septal lead location.
- The incorporation of these ECG criteria in a stepwise algorithm enables identification of a mid-septal lead location with a total sensitivity of 87% and a specificity of 90%.

and left ventricular hemodynamic properties.<sup>3–7</sup> The strategies that have been adopted to avoid the negative consequences of apical pacing include avoidance of RV pacing and/or implantation of RV leads in non-apical sites.

The RV septum is one of the non-apical sites targeted during lead implantation. The intraoperative documentation of lead placement at the desired location is pursued by the use of fluoroscopy.<sup>8</sup> However, in case of mid-septal lead positioning, fluoroscopic validation of accurate location may prove challenging due to the crescent-like shape of the RV chamber which may obscure inadvertent lead positioning in the right anterior wall.<sup>9</sup> Surface electrocardiogram during RV pacing has also been proposed as an ancillary tool for recognition of mid-septal lead placement. However, conflicting results have been reported on proposed electrocardiographic (ECG) criteria suggestive of mid-septal lead positioning.<sup>9–12</sup>

The aim of the study was to determine ECG characteristics of mid-septal pacing in a cohort of implantable cardioverter defibrillator (ICD) recipients randomized to an apical vs. mid-septal RV lead positioning.

## Methods

### Patient population

The methodology of the SPICE study has been previously reported.<sup>13,14</sup> In brief, patients with a standard indication for ICD implantation were included in the study and were randomized in a 1:1 ratio to an apical vs. mid-septal RV lead positioning. All patients had provided written informed consent for their participation in the study.

The ECG substudy of the SPICE study was specifically designed to investigate the ECG characteristics of mid-septal pacing in the setting of this randomized, prospective trial, where the lead positioning was documented fluoroscopically in both right and left anterior oblique projections and was reviewed by an independent adjudication committee blinded to the randomized site. The following surface 12-lead electrocardiograms were recorded for further analysis of predefined secondary endpoints: (a) intrinsic ECG before implantation and (b) RV only paced ECG (DDD with shortest programmable atrioventricular delay or VVI at a rate faster than the spontaneous rate) to ensure recording of fully paced complexes and avoid fusion.

In total, 299 patients were enrolled in the SPICE study. The ECGs recorded by individual investigators were scanned centrally. Two reviewers blinded to lead positioning performed the on-screen measurements of selected ECG parameters. In case of disagreement in ECG interpretation the opinion of a third reviewer, unaware of patients' allocation, was taken into consideration. The local investigators provided ECGs of 263 patients. Among those, the estimated parameters could not be

measured in 36 patients for the following reasons: (a) RV paced 12-lead ECG not available or incomplete (precordial or limb leads missing),  $n = 17$ ; (b) not fully paced ECG,  $n = 11$ ; (c) low-quality ECG scanning,  $n = 4$ ; and (d) ECG inconsistent with RV pacing probably due to inadvertent classification as RV pacing ECG,  $n = 4$  (e.g. QS in lead I and monophasic R in V1 in cardiac resynchronization therapy recipients).

### Electrocardiographic measurements

The following ECG parameters were measured in the fully RV paced ECG:

- QRS width*: The QRS width was defined as the maximal QRS duration among all leads.
- Net amplitude of QRS complex*: In each lead, the net amplitude of the QRS complex was calculated as maximal positive minus maximal negative deflection voltage of the QRS complex (R–Q–S).
- Frontal QRS axis*: The QRS axis was calculated in degrees by the vector method using the net voltage of QRS complexes in leads I and aVF.
- Morphology of the QRS complex*: In all leads, QRS morphology was determined and classified in one of the following patterns: qR, QR, QR, QS, rS, Rs, RS, monophasic R, rsr, and qrs.
- Vector of the QRS complex*: In each lead the vector of the QRS complex was ascertained based on the net voltage of the QRS complex. The vector was classified as positive if the net amplitude was  $>0.05$  mV, negative if  $<-0.05$  mV, and isoelectric if between  $-0.05$  and  $0.05$  mV.

In the spontaneous ECG, the QRS width and frontal QRS axis were calculated.

### Statistical analysis

Continuous data are presented as mean  $\pm$  standard deviation, while categorical data as count and percentages. Pearson's  $\chi^2$  test for categorical variables and Student's *t*-test for continuous variables were employed to compare parameters between groups of interest. We calculated the sensitivity, specificity of the evaluated ECG criteria based on the following formulas: (a) sensitivity = true positive/(true positive and false negative) and (b) specificity = (true negative/true negative and false positive). All tests were considered to be significant at the 0.05 level. Statistical analyses were performed with SPSS statistical software (version 16.0, SPSS).

## Results

### Patient population

In total 227 patients, 121 in the apical group and 106 in the mid-septal group had a complete paced 12-lead ECG available for digital analysis. The baseline characteristics of the patient population are presented in *Table 1*. During intrinsic rhythm, there was no significant difference in the mean QRS duration and the mean frontal QRS axis between the compared groups.

### Difference in electrocardiographic characteristics between mid-septal and apical pacing groups

Patients randomized in the apical group had significantly prolonged QRS duration during RV pacing as compared with those in the mid-septal group ( $177.0 \pm 25.0$  vs.  $170.4 \pm 21.7$  ms, respectively,  $P = 0.03$ ). Furthermore, the difference in QRS duration between RV pacing and spontaneous rhythm displayed a trend towards statistical significance when comparing the apical vs. the mid-septal group ( $58.2 \pm 29.2$  vs.  $50.5 \pm 30.3$  ms, respectively,  $P = 0.057$ ). Patients

**Table 1** Baseline characteristics of the patient population

	Apical site (n = 121)	Mid-septal site (n = 106)	P-value
Male gender	76.9%	82.1%	0.33
Age (years)	67.1 ± 11.3	64.7 ± 12.7	0.13
NYHA class	2.4 ± 0.8	2.4 ± 0.8	0.94
Diabetes	28.1%	31.1%	0.62
Hypertension	68.6%	64.2%	0.48
Ischaemic cardiomyopathy	59.5%	53.8%	0.38
Ejection fraction	28.2 ± 11.4	28.1 ± 10.4	0.94
CRT-D	33.9%	33.0%	0.89
Baseline QRS duration (ms)	119.9 ± 31.5	121.1 ± 28.6	0.76
Baseline QRS axis (°)	1.5 ± 53.8	-3.2 ± 57.2	0.53
LBBB	30.8%	31.4%	0.92

NYHA, New York Heart Association; CRT-D, cardiac resynchronization therapy—defibrillator; LBBB, left bundle branch block.

with an apical RV lead, as compared with those paced in the septum, had a significantly more leftward paced QRS axis ( $-71.6 \pm 33.3^\circ$  vs.  $9.4 \pm 86.5^\circ$ , respectively,  $P < 0.001$ ) and a significantly higher difference in QRS axis between RV paced and intrinsic rhythm ( $-73.4 \pm 59.4^\circ$  vs.  $11.4 \pm 97.8^\circ$ , respectively,  $P < 0.001$ ). A leftward axis ( $-30^\circ$  or more) was present more often among apically paced patients as compared with those paced from the septum (96.7 vs. 47.6%,  $P < 0.001$ ).

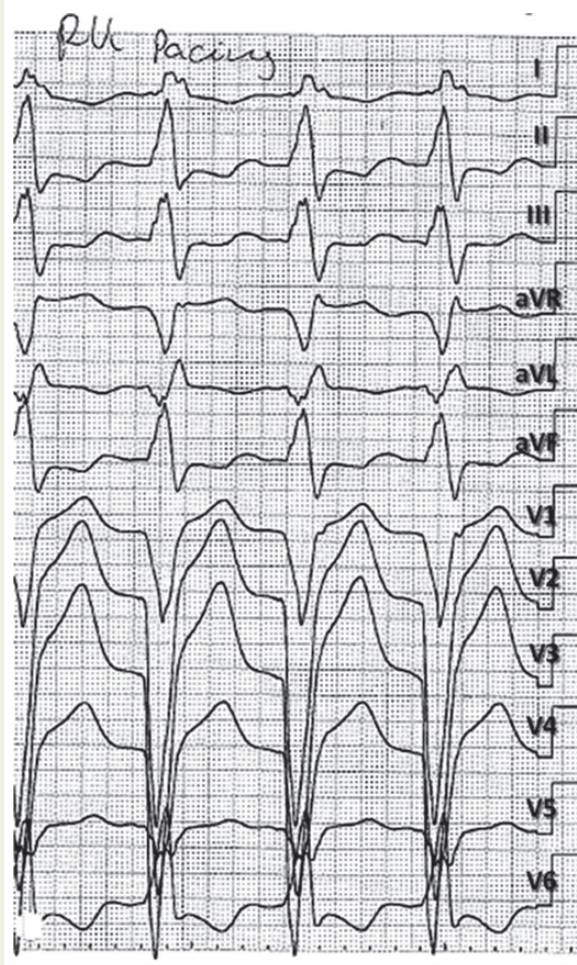
A significantly higher percentage of patients in the mid-septal as compared with the apical group displayed a QR pattern (qR, QR, or Qr but not QS) in lead I (56.6 vs. 22.3%,  $P < 0.001$ ) and in lead aVL (53.3 vs. 3.3%,  $P < 0.001$ ). A predominantly positive QRS in any of the inferior leads (II or III or aVF) was significantly more frequent among septally paced patients in comparison with those paced from the RV apex (53.8 vs. 4.1%,  $P < 0.001$ ). A predominantly positive QRS in lead V6 was found significantly more often when pacing from the septum as compared with apical pacing (62.3 vs. 4.1%,  $P < 0.001$ ).

## Diagnostic algorithm

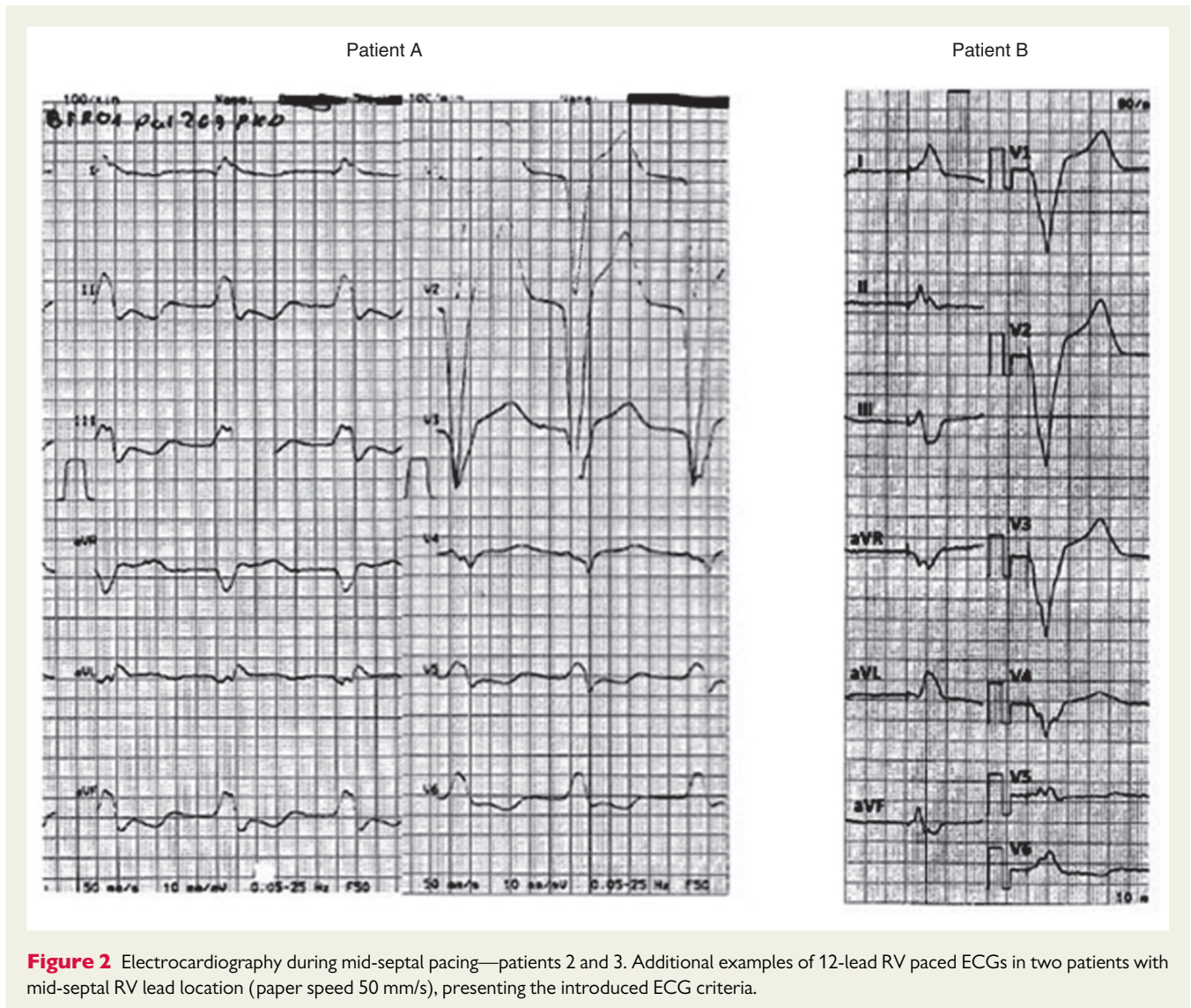
A summary of the electrocardiographic criteria that could be used as indicators of a RV mid-septal lead positioning as well as the respective values of sensitivity and specificity are presented in Table 2. However, since none of these ECG findings presents predictive accuracy that could be of value for the clinician in everyday clinical practice, we developed a stepwise algorithm which can accurately identify the lead position based on the following criteria: (a) predominantly positive QRS in lead V6, (b) predominantly positive QRS in any of the inferior leads, and (c) presence of QR pattern in lead aVL (examples presented in Figures 1 and 2). The absolute numbers of true and false-positive diagnoses as well as the values of sensitivity and specificity at each step of the proposed algorithm are presented in Figure 3. The use of the proposed criteria resulted in a total sensitivity of 87% and a

**Table 2** Sensitivity and specificity values of ECG parameters which could be used as indicators of a mid-septal lead positioning

ECG parameter	Sensitivity (%)	Specificity (%)
Predominantly positive QRS in lead V6	62.3	95.9
QR (qR, QR, Qr but not QS) pattern in lead I	56.6	77.7
QR (qR, QR, Qr but not QS) pattern in lead aVL	53.3	96.7
Predominantly positive QRS in any of the inferior leads (II, III, aVF)	53.8	95.9
ECG axis less leftward than $-30^\circ$	52.4	96.7



**Figure 1** Electrocardiography during mid-septal pacing. Twelve-lead ECG of a patient paced from the RV mid-septum (110 pulses per minute—paper speed 50 mm/s). All the ECG criteria integrated in the proposed algorithm are displayed: (A) predominantly positive QRS in lead V6, (B) predominantly positive QRS in any of the inferior leads (lead II and aVF in the current example), and (C) qR in lead aVL.



**Figure 2** Electrocardiography during mid-septal pacing—patients 2 and 3. Additional examples of 12-lead RV paced ECGs in two patients with mid-septal RV lead location (paper speed 50 mm/s), presenting the introduced ECG criteria.

specificity of 90% for the identification of a mid-septal lead location. When the presence of a QR pattern in lead I was used at the step 3 of the proposed algorithm instead of the presence of a QR pattern in lead aVL, then the total sensitivity was improved to 93% with a trade-off of a considerably reduced specificity of 71%.

## Discussion

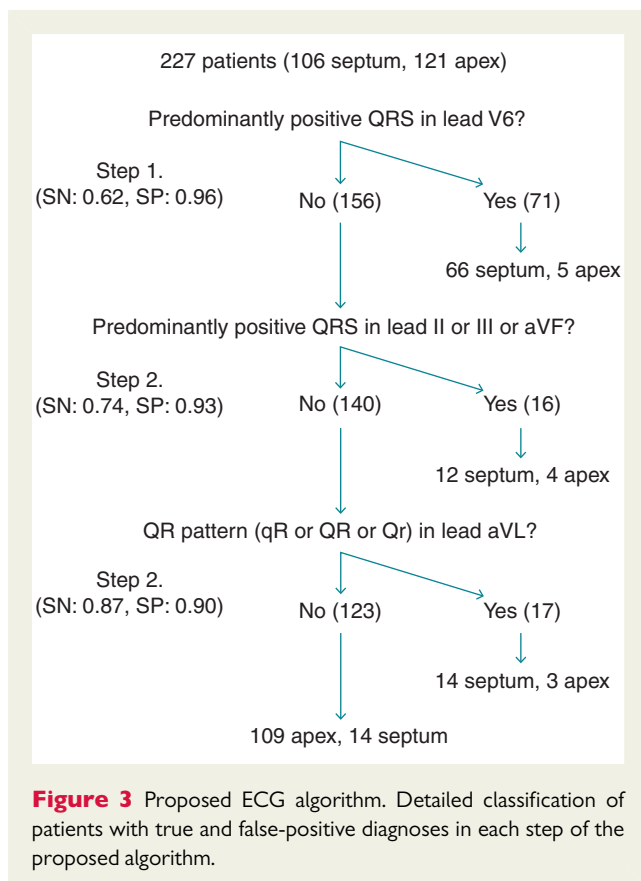
The main finding of this specifically designed substudy of the prospective SPICE study is the identification and validation of ECG correlates of RV mid-septal lead location in a cohort of ICD recipients randomized to a mid-septal vs. an apical lead positioning. Furthermore, we integrated these criteria in an easy to use, practical, step-wise algorithm, which could be of value in everyday clinical practice.

The existing data pertaining to ECG characteristics of a RV mid-septal lead position are limited. In a cross-sectional study of 34 paced patients, Ng *et al.* reported that apical pacing had a significantly more prolonged QRS duration as compared with mid-septal pacing. The echocardiographic confirmation of pacing site revealed a true mid–mid-septal

lead location in only 2 of 17 patients in the mid-septal pacing group.<sup>15</sup> Domenichini *et al.*<sup>12</sup> randomized 59 patients to an apical vs. mid-septal lead positioning with an echocardiographic confirmation of pacing site. Based on their findings, mid-septal pacing resulted in a significantly shorter QRS duration ( $150 \pm 15$  vs.  $158 \pm 17$ ms) and a significantly more leftward QRS axis ( $-76 \pm 14^\circ$  vs.  $-31 \pm 63^\circ$ ) as compared with apical pacing. Furthermore, they reported that a negative QRS complex in lead I, without differentiating between QS and QR patterns, was not an accurate marker of true mid-septal RV lead position.<sup>12</sup> However, it should be pointed out that a truly mid-septal position was achieved in only 54% of patients in the mid-septal group, due to inadvertent lead positioning in the anterior wall.

## Anatomic considerations

The RV has a complex anatomy, displaying a triangular shape when viewed from the front and a crescent shape when viewed in cross section.<sup>16</sup> An important spatial characteristic of the RV is that it ‘wraps around’ the left ventricle. The curvature over the left ventricle results in a more leftward location of the RV apex in relation



to the RV mid-septum. Furthermore, the apex of the right ventricle is caudally situated in relation to other parts of the right and left ventricle, and is frequently inferior even to that of the left ventricle.<sup>17</sup> Based on these anatomic considerations, when pacing from RV septum, the site of onset of ventricular depolarization results in a wavefront propagation directed more leftward and more downwards as compared with the depolarization vector during pacing from an RV apical site.

These considerations are supportive of our findings, showing a significantly increased percentage of septally paced patients with a predominantly positive QRS in V6 (more leftward depolarization) and in any of the inferior leads (more high-to-low depolarization) as compared with those paced from the RV apex. The latter finding is also consistent with the significantly less leftward paced QRS axis in the mid-septal as compared with the apical group. Furthermore, pacing from the RV septum resulted in a significantly narrower QRS duration which may reflect the earlier invasion of the normal conduction system. These data are in agreement with those of Domenichini *et al.*<sup>12</sup> Given that the observed differences of QRS duration were subtle, although statistically significant, the existing discrepancy in the literature could be attributed to differences in patients characteristics and methodological issues mostly related to the perioperative validation of a truly mid-septal positioning.

### Proposed stepwise algorithm

The first two steps of the proposed diagnostic algorithm included the commented criteria of a predominantly positive QRS in V6 and secondly a predominantly positive QRS in any of the inferior leads. These two criteria, when applied consecutively resulted in a sensitivity of

74% and a specificity of 93%. The third step included the presence of a QR pattern in lead aVL, and resulted in sensitivity of 87% and a specificity of 90%. In our patient cohort, we found a significantly higher percentage of septally paced patients displaying a QR pattern in lead aVL, as well as in lead I, in comparison with patients paced from the RV apex. Previous studies have shown that pacing from the mid-septal part of the RV outflow tract is associated with a negative or isoelectric vector in lead I.<sup>10,18</sup> However, Burri *et al.*<sup>19</sup> reported that ECG indices, including a negative QRS complex in lead I, cannot be used reliably to validate a mid-septal lead positioning. Furthermore, Balt *et al.*<sup>11</sup> demonstrated the existence of a significant overlap in ECG pattern between mid-septal and non-mid-septal (anterior and free-wall) pacing sites in the RV outflow tract. The existing discrepancy may be attributed to diversities in patient populations, variant methods of validating the intended pacing site, different pacing location in the control group (RV apex, anterior RV wall, or non-septal RV outflow tract), and inadvertent lead location in pacing sites different from the intended one.

### Limitations

In our study, fluoroscopy was selected as the gold standard for validation of the pacing location. However, due to the crescent shape of the RV, fluoroscopical differentiation of lead location at the RV septum vs. RV free wall is not accurate. Therefore, despite the verification of final lead position by a blinded adjudication committee based on both right and left anterior oblique fluoroscopic projections, the likelihood of inadvertent free-wall positioning of leads categorized in the mid-septal group cannot be excluded. Although the implementation of imaging methods, such as echocardiography or computerized tomography scanning, could overcome this caveat, their everyday use is time consuming, expensive, and usually not feasible.

It should also be noted that the criteria incorporated in the proposed diagnostic algorithm were derived from a comparison between apical and mid-septal lead positioning and therefore these criteria are not necessarily accurate in the differentiation of a mid-septal vs. an anterior lead location. This hypothesis needs to be tested in future studies.

### Conclusions

The present study evaluated ECG correlates of a mid-septal lead location in a cohort of ICD recipients randomized to an apical vs. a mid-septal pacing site. A mid-septal lead location may be identified using a simple stepwise algorithm, based on the presence of positive QRS in lead V6, positive QRS in any of the inferior leads, and a QR pattern in lead aVL.

### Acknowledgements

The authors would like to express their sincere appreciation to Frank Birkenhauer (St Jude Medical Germany) for his valuable contribution in database administration and statistical analyses and to Gabriele Reischl (St Jude Medical Germany) for her invaluable logistic centre support. The adjudication committee consisted of Dr G. Nölker (Bad Oeynhausen, Germany) and Dr J. Michaelsen (Lingen, Germany) and the steering committee

comprised C. Kolb (Munich, Germany), S. Asbach (Freiburg, Germany), and G. Andrikopoulos (Athens, Greece).

**Conflict of interest:** G.A. has received travel support and lecture honoraria from St Jude Medical and Medtronic. S.T. has received travel support and lecture honoraria from St Jude Medical and Medtronic. S.A. has received lecture honorary/travel support from Biotronik, Boston Scientific, Medtronic and St Jude Medical; he performs/has performed clinical studies supported by Biotronik, Medtronic, Sorin and St Jude Medical. V.S. has received travel support from Sorin and St Jude Medical. C.L. has received travel support from St Jude Medical. U.S. has received none. C.G. has received travel support from Biotronik and St Jude Medical. A.K. has received lecture honorary/travel support from Biotronik, Boston Scientific, Medtronic and St Jude Medical; he is a consultant to Medtronic and St Jude Medical and performs/has performed clinical studies supported by Biotronik, Medtronic, Boston Scientific and St Jude Medical. N.K. has received lecture honorary/travel support from Boston Scientific, Sorin and St Jude Medical; he is a consultant to Boston Scientific and St Jude Medical and performs/has performed clinical studies supported by Biotronik, Boston Scientific, Medtronic, Sorin and St Jude Medical. S.P. has received none. J.B. has received lecture honorary/travel support from Biotronik, Boston Scientific, Medtronic and St Jude Medical; he performs/has performed clinical studies supported by Biotronik, Medtronic, Sorin and St Jude Medical. C.K. has received lecture honorary/travel support from Biotronik, Boston Scientific, Medtronic, St Jude Medical and Sorin; he is a consultant to Biotronik, Boston Scientific and Sorin, and performs/has performed clinical studies supported by Biotronik, Medtronic, Sorin and St Jude Medical.

## Funding

This work was supported by St Jude Medical Germany, Eschborn, Germany.

## References

1. Wilkoff BL, Cook JR, Epstein AE, Greene HL, Hallstrom AP, Hsia H et al. Dual Chamber and VVI Implantable Defibrillator Trial Investigators. Dual-chamber pacing or ventricular backup pacing in patients with an implantable defibrillator: the Dual Chamber and VVI Implantable Defibrillator (DAVID) Trial. *JAMA* 2002; **288**:3115–23.
2. Sweeney MO, Hellkamp AS, Ellenbogen KA, Greenspon AJ, Freedman RA, Lee KL et al. Adverse effect of ventricular pacing on heart failure and atrial fibrillation among patients with normal baseline QRS duration in a clinical trial of pacemaker therapy for sinus node dysfunction. *Circulation* 2003; **107**:932–7.
3. Prinzen FV, Peschar M. Relation between the pacing induced sequence of activation and left ventricular pump function in animals. *Pacing Clin Electrophysiol* 2002; **25** (Pt 1): 484–98.
4. Skolidis EI, Kochiadakis GE, Koukouraki SI, Chrysostomakis SI, Igoumenidis NE, Karkavitsas NS et al. Myocardial perfusion in patients with permanent ventricular pacing and normal coronary arteries. *J Am Coll Cardiol* 2001; **37**:124–9.
5. van Oosterhout MF, Prinzen FW, Arts T, Schreuder JJ, Vanagt WY, Cleutjens JP et al. Asynchronous electrical activation induces asymmetrical hypertrophy of the left ventricular wall. *Circulation* 1998; **98**:588–95.
6. Vernooij K, Dijkman B, Cheriex EC, Prinzen FW, Crijns HJ. Ventricular remodeling during long-term RV pacing following His bundle ablation. *Am J Cardiol* 2006; **97**: 1223–7.
7. Barold SS, Ovsyshcher IE. Pacemaker-induced mitral regurgitation. *Pacing Clin Electrophysiol* 2005; **28**:357–60.
8. Osmancik P, Stros P, Herman D, Curila K, Petr R. The insufficiency of left anterior oblique and the usefulness of right anterior oblique projection for correct localization of a CT-verified RV lead into the midseptum. *Circ Arrhythm Electrophysiol* 2013; **6**: 719–25.
9. Hillock RJ, Stevenson IH, Mond HG. The RV outflow tract: a comparative study of septal, anterior wall, and free wall pacing. *Pacing Clin Electrophysiol* 2007; **30**:942–7.
10. McGavigan AD, Roberts-Thomson KC, Hillock RJ, Stevenson IH, Mond HG. Right ventricular outflow tract pacing: radiographic and electrocardiographic correlates of lead position. *Pacing Clin Electrophysiol* 2006; **29**:1063–8.
11. Balt JC, van Hemel NM, Wellens HJ, de Voogt WG. Radiological and electrocardiographic characterization of RV outflow tract pacing. *Europace* 2010; **12**:1739–44.
12. Domenichini G, Sunthorn H, Fleury E, Foulkes H, Stettler C, Burri H. Pacing of the interventricular septum versus the RV apex: a prospective, randomized study. *Eur J Intern Med* 2012; **23**:621–7.
13. Kolb C, Tzeis S, Andrikopoulos G, Asbach S, Lemke B, Hansen C et al. Rationale and design of the SPICE study-mid-septal positioning of ventricular ICD electrodes. *J Interv Card Electrophysiol* 2011; **31**:247–54.
14. Kolb C, Solzbach U, Biermann J, Semmler V, Kloppe A, Klein N et al. Safety of mid-septal electrode placement in implantable cardioverter defibrillator recipients—results of the SPICE (septal positioning of ventricular ICD electrodes) study. *Int J Cardiol* 2014; **174**:713–20.
15. Ng AC, Allman C, Vidaic J, Tie H, Hopkins AP, Leung DY. Long-term impact of RV mid-septal versus apical pacing on left ventricular synchrony and function in patients with second- or third-degree heart block. *Am J Cardiol* 2009; **103**:1096–101.
16. Haddad F, Hunt SA, Rosenthal DN, Murphy DJ. Right ventricular function in cardiovascular disease, part I: anatomy, physiology, aging, and functional assessment of the right ventricle. *Circulation* 2008; **117**:1436–48.
17. Ho SY, Nihoyannopoulos P. Anatomy, echocardiography, and normal right ventricular dimensions. *Heart* 2006; **92** (Suppl 1):i2–13.
18. Rosso R, Medi C, Teh AV, Hung TT, Feldman A, Lee G et al. Right ventricular mid-septal pacing: a comparative study of outflow tract and mid ventricular sites. *Pacing Clin Electrophysiol* 2010; **33**:1169–73.
19. Burri H, Park CI, Zimmermann M, Gentil-Baron P, Stettler C, Sunthorn H et al. Utility of the surface electrocardiogram for confirming RV mid-septal pacing: validation using electroanatomical mapping. *Europace* 2011; **13**:82–6.